OP-040 [Apitherapy]

Review of therapeutic outcomes in the practice of Integrative Veterinary Medicine. Traditional Chinese Medicine and Apitherapy integrated into patient care: comparative protocols; analysis of simple data and relevant clinical cases

María Alejandra Lopez Pazos[1], María Alejandra Lopez Pazos[2], María Alejandra Lopez Pazos[3]
[1]Terapis®
[2]Maroon Gold®
[3]Apimondia Apitherapy Scientific Commission

The clinical management of patients in Veterinary Medicine involves acting in a systemic and interdisciplinary manner to achieve better results, from diagnosis to treatment; during the follow-up of individual patients and groups of patients; in medical centers and therapeutic, productive, and work environments of varying complexity; Providing patients with the best therapeutic combinations through medical protocols based on medicine and science.

MATERIALS-METHODS: Beehive products are part of the therapeutic arsenal in this analysis. They are included in the field medicine cabinet; in hospital medicine cabinets; at the clinical, surgical, nutritional, and physiotherapy levels; they are part of specialized medical protocols; and at the laboratory level - in quality control of therapeutic products and formulations.

This article presents an overview of the clinical outcomes of the integration of Traditional Chinese Medicine and Apitherapy in daily clinical practice in patients of different species (Canines, Felines, Equines, Bovines, Ovines/Humans).

RESULTS: The results and impact of scientifically supported Integrative Medicine are analyzed from different perspectives by medical specialty, with more than 3,000 clinical histories of patients treated with Apitherapy, accompanied by relevant clinical cases.



APIMONDIA SCANDINAVIA 2025
SWEDEN | DENMARK | NORWAY
23-27 SEPTEMBER
COPENHAGEN

Review of therapeutic outcomes in the practice of Integrative Veterinary Medicine.
Traditional Chinese Medicine and Apitherapy integrated into patient care: Comparative protocols; analysis of simple data and relevant clinical cases.

TERAPIS
El lado apícola de la vida.

- Dr. María Alejandra López Pazos
  - Veterinary Physician *
  - Diploma in Traditional Chinese Medicine and Apitherapy / People
  - Member of the Apitherapy Scientific Committee - APIMONDIA (Apitherapy in Veterinary Medicine)
  - Council Member Specialty Committee of Apitherapy / World Federation of Chinese Medicine Societies
  - TERAPIS ® / www.terapis.cl / @centrovetera
  - centrovetera@gmail.com

A pleasure to meet the Copenhagen and world beekeeping community. I will share clinical results from my integrative and comparative medicine experience, combining veterinary medicine and human TCM, gathered in my therapeutic practice.









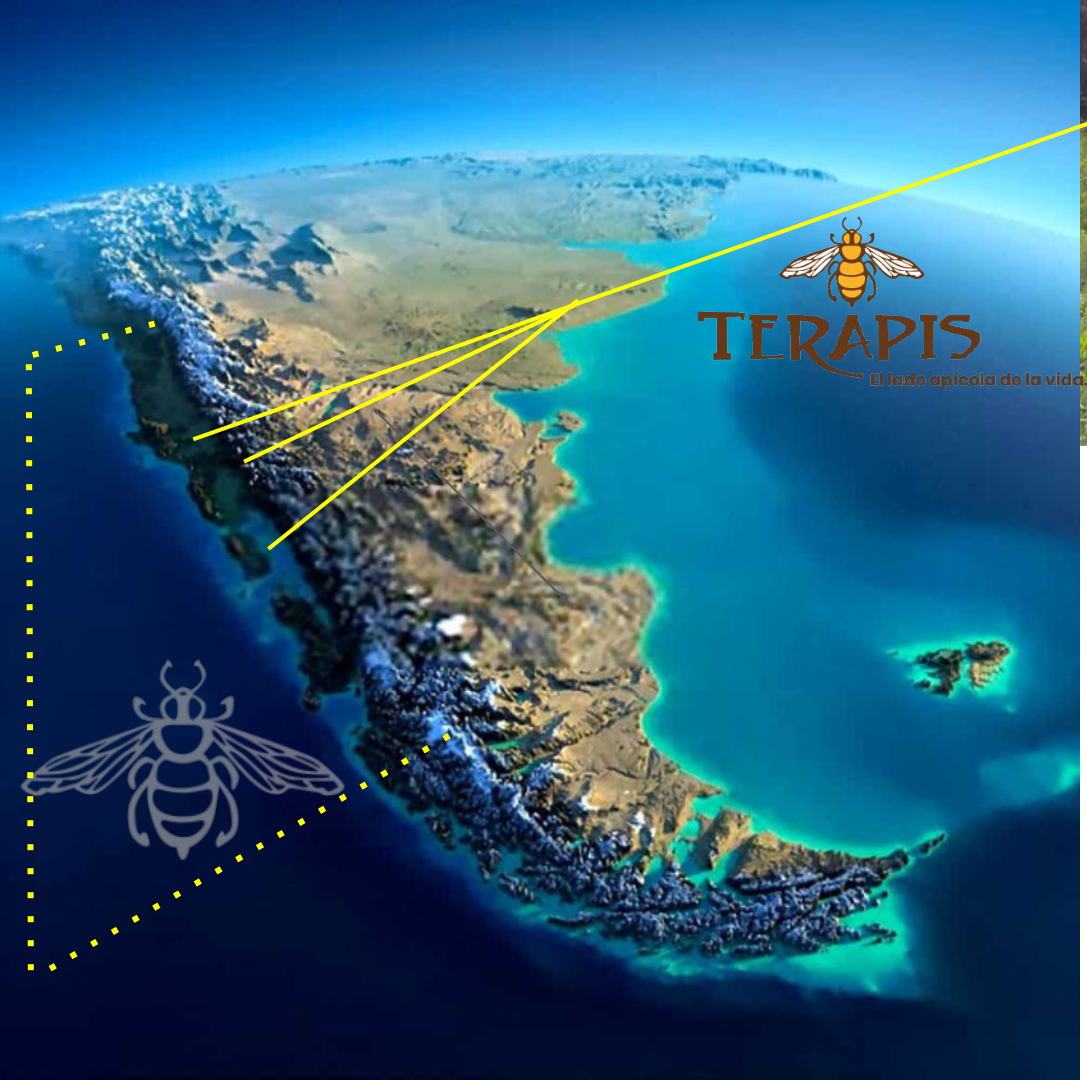



The development of clinical apitherapy in animals from the year 2000 onwards, was the starting point for a larger project; comparative protocols (animals/people) were subsequently developed for 15 years.

We have adopted a hybrid approach, linking our professions (veterinary medicine/geography and engineering) with beekeeping and apitherapy. In the veterinary practice, phytotherapy and bee products are also integrated into the therapeutic arsenal.

I have witnessed and participated in the ancestral union of both since 2008 in the World TCM Society.

The good quality of bee products is key. And that is provided by the habitat and biodiversity in some areas of southern Chile.





















ulmo-eucryphia-cordifolia; Tineo; Tiaca, Canelo: Valdivian Rain Forest

Integrative and Comparative Medicine, combined with the concept of **One Health**, study human, animal, and environmental health together to implement treatments, promote research, and address global challenges (zoonosis, bacterial resistance, etc.) through multidisciplinary collaboration and sustainable strategies.









Beekeeping products are part of the therapeutic arsenal in this analysis. They are included in my work in: **field medicine kits; hospital medicine kits; clinical, surgical, nutritional, and physiotherapy settings**; and are **part of specialized medical protocols and therapeutic formulations**.

This article presents an overview of the clinical results of integrating Traditional Chinese Medicine and Apitherapy into daily clinical practice alongside modern medicine in patients of different species (canine, feline, equine, donkeys and people).

Farm animals and protected wildlife, which have also received similar treatment, are not included.

The most relevant clinical results I present today are based on scientific evidence; With this I have been able to develop and correct the treatment protocols that generate the results I present.

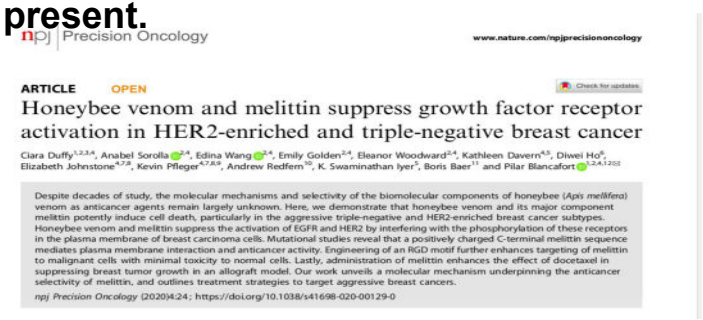

npj | Precision Oncology

www.nature.com/npjprecisiononcology

ARTICLE OPEN

Honeybee venom and melittin suppress growth factor receptor activation in HER2-enriched and triple-negative breast cancer

Ciara Duffy[1,2,3,4], Anabel Sorolla[2,4], Edina Wang[2,4], Emily Golden[2,4], Eleanor Woodward[2,4], Kathleen Davern[4,5], Diwei Ho[6], Elizabeth Johnstone[4,7,8], Kevin Pfleger[4,7,8,9], Andrew Redfern[10], K. Swaminathan Iyer[2], Boris Baer[11] and Pilar Blancafort[1,2,4,12]

Despite decades of study, the molecular mechanisms and selectivity of the biomolecular components of honeybee (*Apis mellifera*) venom as anticancer agents remain largely unknown. Here, we demonstrate that honeybee venom and its major component melittin potently induce cell death, particularly in the aggressive triple-negative and HER2-enriched breast cancer subtypes. Honeybee venom and melittin suppress the activation of EGFR and HER2 by interfering with the phosphorylation of these receptors in the plasma membrane of breast carcinoma cells. Mutational studies reveal that a positively charged C-terminal melittin sequence mediates plasma membrane interaction and anticancer activity. Engineering of an RGD motif further enhances targeting of melittin to malignant cells with minimal toxicity to normal cells. Lastly, administration of melittin enhances the effect of docetaxel in suppressing breast tumor growth in an allograft model. Our work unveils a molecular mechanism underpinning the anticancer selectivity of melittin, and outlines treatment strategies to target aggressive breast cancers.

npj Precision Oncology (2020)4:24 ; https://doi.org/10.1038/s41698-020-00129-0



JAPS

Journal of Advanced Pharmaceutical Sciences

Journal homepage: https://japs.journals.ekb.eg/

Review article

Propolis: An update on its chemical diversity, botanical origin and biological activities

Dina S. Ghallab *, Eman Shawky, Mohamed M. Mohyeldin, Ali M Metwally, Reham S. Ibrahim

Department of Pharmacognosy, Faculty of Pharmacy, Alexandria University, Egypt.

***Corresponding author:** Alkhartoom Square, Department of Pharmacognosy, Faculty of Pharmacy, Alexandria University, Egypt, Alexandria 21521, Egypt. Tel: +201080919812

E-mail: dinaghallab6@gmail.com , Dina.Ghalab@alexu.edu.eg

Abstract:

Propolis is a complex resinous substance meticulously harvested by honeybees from diverse botanical sources, and has garnered increasing interest due to its remarkable chemical heterogeneity and extensive range of biological activities. This review provides an



Journal of Apicultural Research

ISSN: (Print) (Online) Journal homepage: https://www.tandfonline.com/loi/tjar20

Propolis extraction methods: a review

Vassya Bankova, Boryana Trusheva & Milena Popova

To cite this article: Vassya Bankova, Boryana Trusheva & Milena Popova (2021): Propolis extraction methods: a review, Journal of Apicultural Research, DOI: 10.1080/00218839.2021.1901426

To link to this article: https://doi.org/10.1080/00218839.2021.1901426

Published online: 06 Apr 2021.



Brazilian Journal of Microbiology 44, 2, 577-585 (2013)
ISSN 1678-4405

Copyright © 2013, Sociedade Brasileira de Microbiologia
www.sbmicrobiologia.org.br

Research Paper

Chemical and botanical characterization of Chilean propolis and biological activity on cariogenic bacteria *Streptococcus mutans* and *Streptococcus sobrinus*

Leticia Barrientos[1,2], Christian L. Herrera[1], Gloria Montenegro[3], Ximena Ortega[1], Jorge Veloz[1], Marysol Alvear[4], Alejandro Cuevas[1], Nicolás Saavedra[1], Luis A. Salazar[1,2]

[1]Centro de Biología Molecular & Farmacogenética, Scientific and Technological Bioresource Nucleus, Universidad de La Frontera, Temuco, Chile.
[2]Centro de Excelencia en Estudios Genéticos e Inmunológicos, Universidad de La Frontera, Temuco, Chile.
[3]Departamento de Ciencias Vegetales, Facultad de Agronomía e Ingeniería Forestal, Pontificia Universidad Católica de Chile, Santiago, Chile.
[4]Departamento de Ciencias Químicas y Recursos Naturales, Facultad de Ingeniería, Ciencias y Administración, Universidad de La Frontera, Temuco, Chile.

Submitted: June 2, 2012; Approved: September 10, 2012

Abstract

Propolis is a non-toxic natural substance with multiple pharmacological properties including anti-cancer, antioxidant, fungicidal, antibacterial, antiviral, and anti-inflammatory among others. The aim of this study was to determine the chemical and botanical characterization of Chilean propolis samples and to evaluate their biological activity against the cariogenic bacteria *Streptococcus mutans* and *Streptococcus sobrinus*. Twenty propolis samples were obtained from beekeeping producers from the central and southern regions of Chile. The botanical profile was determined by palynological analysis. Total phenolic contents were determined using colorimetric assays. Reverse phase HPLC and HPLC-MS were used to determine the chemical composition. The minimum inhibitory concentration (MIC) was determined on *S. mutans* and *S. sobrinus*. All propolis samples were dominated by structures from native [illegible] and exotic [illegible]. The presence of quercetin, myricetin, [illegible] acid and caffeic acid phenethyl ester, that [illegible] conventional HPLC. Al-



eFood
Vol. 1(1); February (2020), *pp.* 24–37
DOI: https://doi.org/10.2991/efood.k.191029.001; eISSN 2666-3066
https://www.atlantis-press.com/journals/efood

Review

Advances in the Propolis Chemical Composition between 2013 and 2018: A Review

Luka Šturm, Nataša Poklar Ulrih*

Department of Food Science and Technology, Biotechnical Faculty, University of Ljubljana, Jamnikarjeva 101, Ljubljana 1000, Slovenia

ARTICLE INFO

Article History
Received 29 March 2019
Accepted 21 October 2019

Keywords
Propolis
chemical composition
new compounds
first time
newly isolated

ABSTRACT

Propolis is a lipophilic sticky substance collected by bees that has been used by humans for centuries. Owing to its healing, antioxidant, and other medicinal properties, its chemical composition has been widely studied. Most pharmacological properties of propolis have been attributed to its phenols and terpenes, mainly flavonoids, phenolic acids, and their derivatives. More than 500 components of propolis were known from different parts of the world until 2012. In this article, 305 new constituents of propolis described between 2013 and 2018 are being reviewed, with 19 additional compounds that were discovered between 2011 and 2012, and were excluded from a similar previous review article. Altogether more than 850 compounds were isolated from propolis until 2018.

© 2019 *International Association of Dietetic Nutrition and Safety*. Publishing services by Atlantis Press International B.V.
This is an open access article distributed under the CC BY-NC 4.0 license (http://creativecommons.org/licenses/by-nc/4.0/).

The first clinical cases I present are examples or related to burns and major injuries caused by fire and the chaos it produces in real mega-fires in the summer of 2024 & this is part of the work submitted to the Chilean Minister of Agriculture to contribute to the field Veterinary Medical work.

Apitherapy for Major Burns; Massive Fires 2024. Treatment of Burns and Large Wounds with Apitherapy in Veterinary Medicine:

Honey is easy to obtain, so I chose it as a product in these cases, to treat severe burns and wounds caused by massive fires, where animals and people suffer severe injuries and require urgent care. Beehive products, such as honey and propolis, have scientifically proven healing properties due to their natural origin, environmental diversity, and the biochemical transformations carried out by bees.

General treatment for burns:

*Medical evaluation.
*Cleansing of the area.
*Surgical cleaning under general or local anesthesia; removal of necrotic tissue; wound cleansing with liquid chlorhexidine and plenty of saline solution.
*Drying.
*Local treatment with pure, non-adulterated honey from bees; cold extraction.
*The honey should adhere to the tissue, not to the bandage.
*Semi-compression bandages.
*Assessment and bandage changes every 24 hours during the first week.
*Intravenous fluid therapy for major burns (Grade 2 and 3).













4 weeks treatment







3 weeks treatment

Burns grade 2 and 3, pre and post surgical cleaning

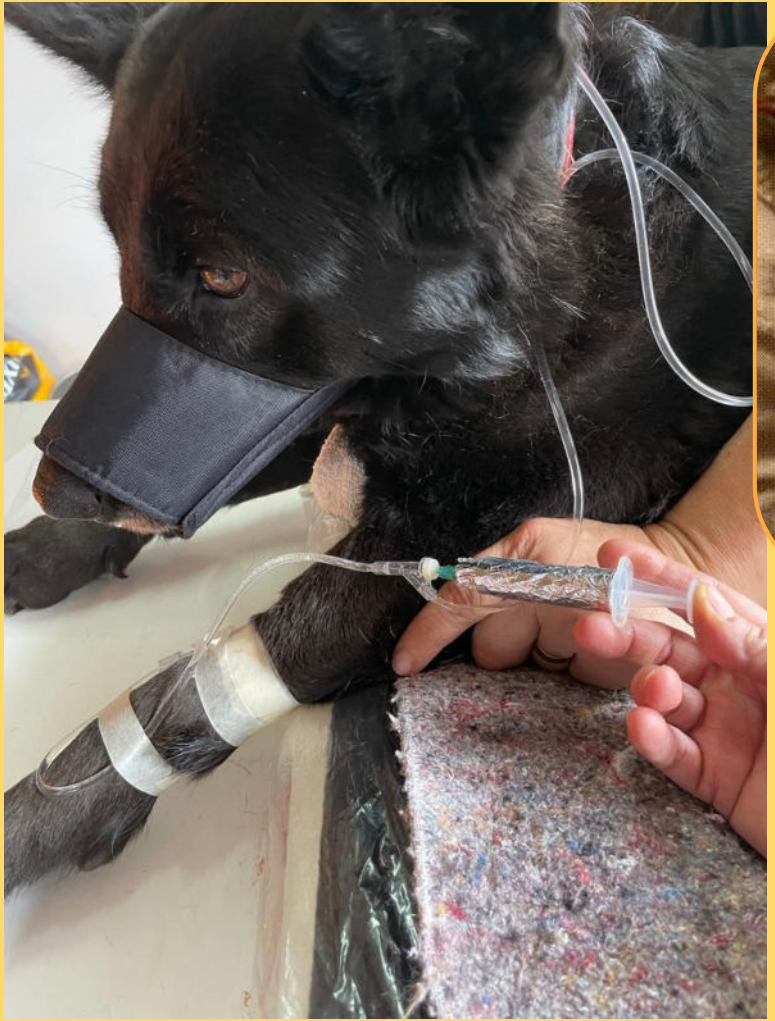







Fluid therapy & IV Honey + Oral Honey + Propolis + Pollen for the recovery of burn and septic patients.



Large injuries, cuts, and flaps. Healing by secondary intention:

Quarter Horse / **52 days of treatment (iconic clinic case)

TERAPIS
El lado apícola de la vida.

intrasurgical dressings
Plasties

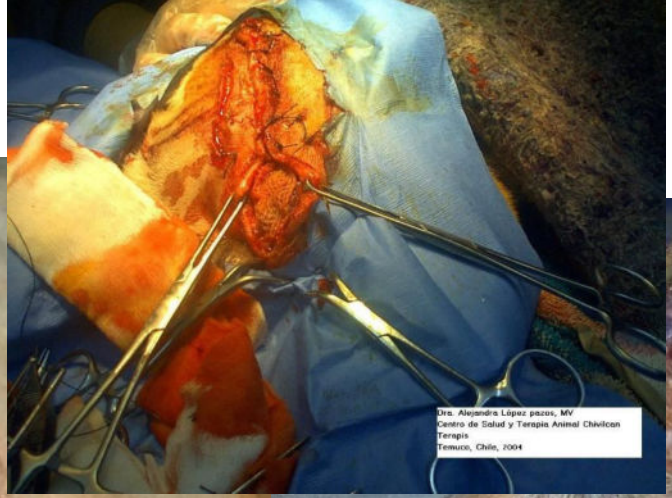





Bites are complex septic lesions:
Treatment:
Broad-spectrum antibiotic coverage for 7 to 10 days + the same procedure as explained above with complex surgical cleaning, removal of necrosis, drying, and local apitherapy with a high-concentration intraoperative wound healing product, injectable apitoxin (Depot Acupuncture / "Surrounding the Dragon") and oral apitherapy (pollen, high-dosage propolis, honey); intravenous honey initially administered 3 times every 24 hours.
.






DISCARD AFTER USE










tesa
tesa
tesa













LILO: female canine Labrador Retriever 8 years.
Basis pathology: Hypothyroidism (Lab results*)
Tumoral lesion (10 x 5 x 3 cm—>)

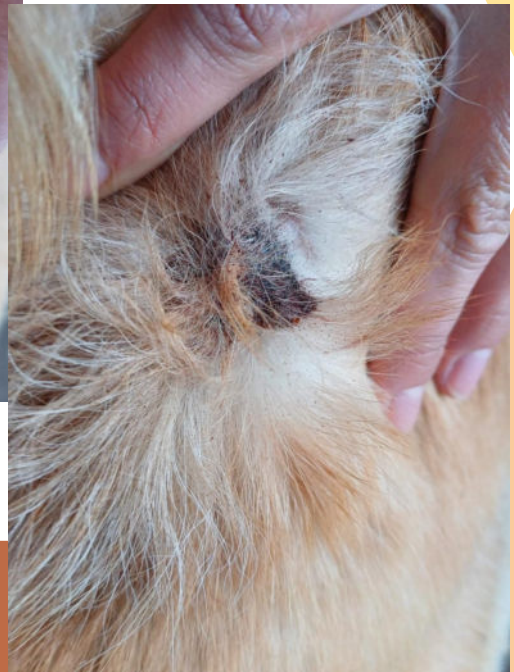

Dermato surgery, total extraction of “possible Lipoma”,



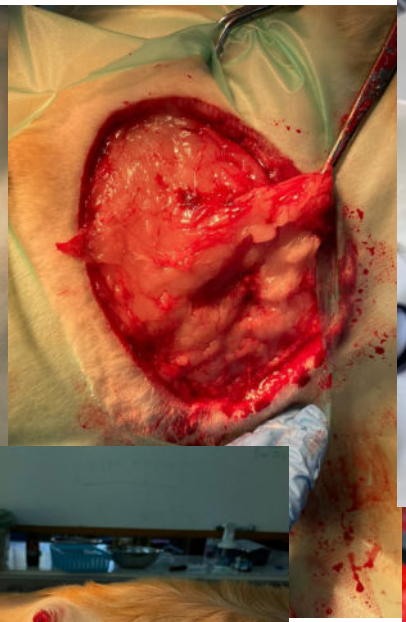

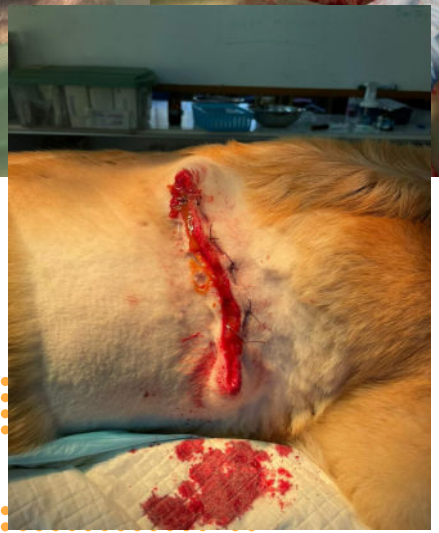



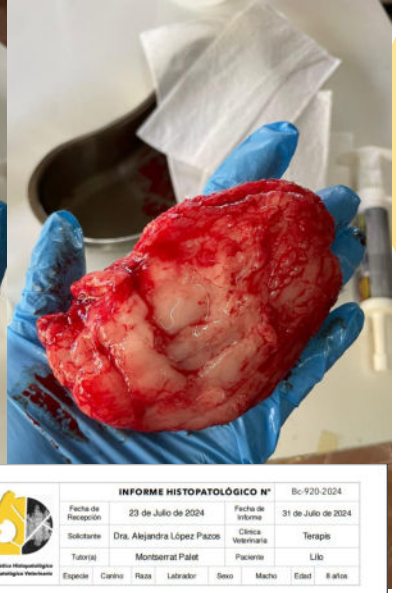





INFORME HISTOPATOLÓGICO Nº Bc-920-2024

Fecha de Recepción	23 de Julio de 2024	Fecha de Informe	31 de Julio de 2024
Solicitante	Dra. Alejandra López Pazos	Clínica Veterinaria	Terapis
Tutor(a)	Montserrat Palet	Paciente	Lilo

Especie	Canino	Raza	Labrador	Sexo	Macho	Edad	8 años

Análisis Histopatológico

Se recibe fijada en formalina una biopsia masa tumoral en zona torácica lateral derecha. De acuerdo a la anamnesis la lesión era blanda y se realizó apiterapia con reducción de su crecimiento. Al corte se observa una lesión mixta, con zonas de consistencia adiposa, hemorragia y fibrosis. Se tomaron muestras representativas para histopatología y se tiheron con Hematoxilina y Eosina. Laboratorio ISO 9001:2008.

La muestra corresponde a piel, en cuya dermis y tejido subcutáneo se observa una lesión mixta, la cual principalmente se compone de tejido adiposo necrosado, focos hemorrágicos y reacción piogranulomatosa, en la cual los macrófagos y células gigantes multinucleadas tienen citoplasma espumoso. En la zonas más centrales de la muestra se observa que la reacción piogranulomatosa está entremezclada con fibroplasia bien vascularizada, fibrosis y focos hialinizados, con escasa vascularización. En ninguna de las muestras analizadas se observan células con caracteres atípicos de tipo neoplásico.

Diagnóstico Histopatológico

La muestra es concordante con LIPOMA NECROSADO CON REACCIÓN PIOGRANULOMATOSA Y FIBROSIS.

Observaciones

De acuerdo a la anamnesis, es probable que la lesión primaria haya sido un lipoma que después de la terapia se haya necrosado y se ha desarrollado una reacción piogranulomatosa y fibrosis cicatricial.

Diagnóstico Histopatológico y Citopatológico Veterinario

INFORME HISTOPATOLÓGICO N°			Bc-920-2024
Fecha de Recepción	23 de Julio de 2024	Fecha de Informe	31 de Julio de 2024
Solicitante	Dra. Alejandra López Pazos	Clinica Veterinaria	Terapis
Tutor(a)	Montserrat Palet	Paciente	Lilo
Especie: Canino	Raza: Labrador	Sexo: Macho	Edad: 8 años

Análisis Histopatológico

Se recibe fijada en formalina una biopsia masa tumoral en zona torácica lateral derecha. De acuerdo a la anamnesis la lesión era blanda y se realizó apiterapia con reducción de su crecimiento. Al corte se observa una lesión mixta, con zonas de consistencia adiposa, hemorragia y fibrosis. Se tomaron muestras representativas para histopatología y se tiñeron con Hematoxilina y Eosina. Laboratorio ISO 9001:2008.

La muestra corresponde a piel, en cuya dermis y tejido subcutáneo se observa una lesión mixta, la cual principalmente se compone de tejido adiposo necrosado, focos hemorrágicos y reacción piogranulomatosa, en la cual los macrófagos y células gigantes multinucleadas tienen citoplasma espumoso. En la zonas más centrales de la muestra se observa que la reacción piogranulomatosa está entremezclada con fibroplasia bien vascularizada, fibrosis y focos hialinizados, con escasa vascularización. En ninguna de las muestras analizadas se observan células con caracteres atípicos de tipo neoplásico.

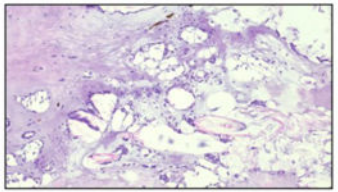

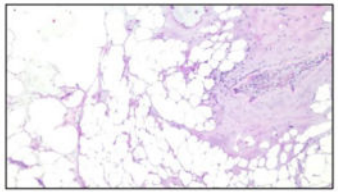

Diagnóstico Histopatológico

La muestra es concordante con LIPOMA NECROSADO CON REACCIÓN PIOGRANULOMATOSA Y FIBROSIS.

Observaciones

De acuerdo a la anamnesis, es probable que la lesión primaria haya sido un lipoma que después de la terapia se haya necrosado y se ha desarrollado una reacción piogranulomatosa y fibrosis cicatricial.

Alexandra R. Ortloff Trautmann
Médico Veterinaria, Dr. Cs. Vet.

Histopathological report:
Lilo (July 31, 2024): Female Labrador Retriever, 8 years old.The lesion was soft, and apitherapy was performed, resulting in growth reduction. A cross-section revealed a mixed lesion with areas of fatty consistency, hemorrhage, and fibrosis. Representative samples were taken for histopathology and stained with hematoxylin and eosin. ISO 9001:2008 laboratory. **The sample is from skin, with a mixed lesion in the dermis and subcutaneous tissue, composed primarily of necrotic adipose tissue, hemorrhagic foci, and a pyogranulomatous reaction, in which macrophages and multinucleated giant cells have foamy cytoplasm. In the more central areas of the sample, the pyogranulomatous reaction is interspersed with well-defined fibroplasia.**











Other relevant Clinical cases in veterinary medicine treated with integrative medicine: NEUROLOGY

Clinical Case: Cane Corso 7-month-old.: DRAGO
puppy with 10/10 pain and major prostration for 72 hours **>45 kg
Exams: Magnetic resonance imaging
Loss of normal architecture at the base of the articular processes on the right side at the T11-12 level, with bone lysis.
Discospondylitis at L5-6, inflammatory tissue, myelocompression with pathological fracture dislocation and mild displacement, and paravertebral myositis.
Foci of hostomyelitis at the base of the articular processes at T11-12 on the right side, which does not involve the vertebral canal.
(Brusella sp (+))
.

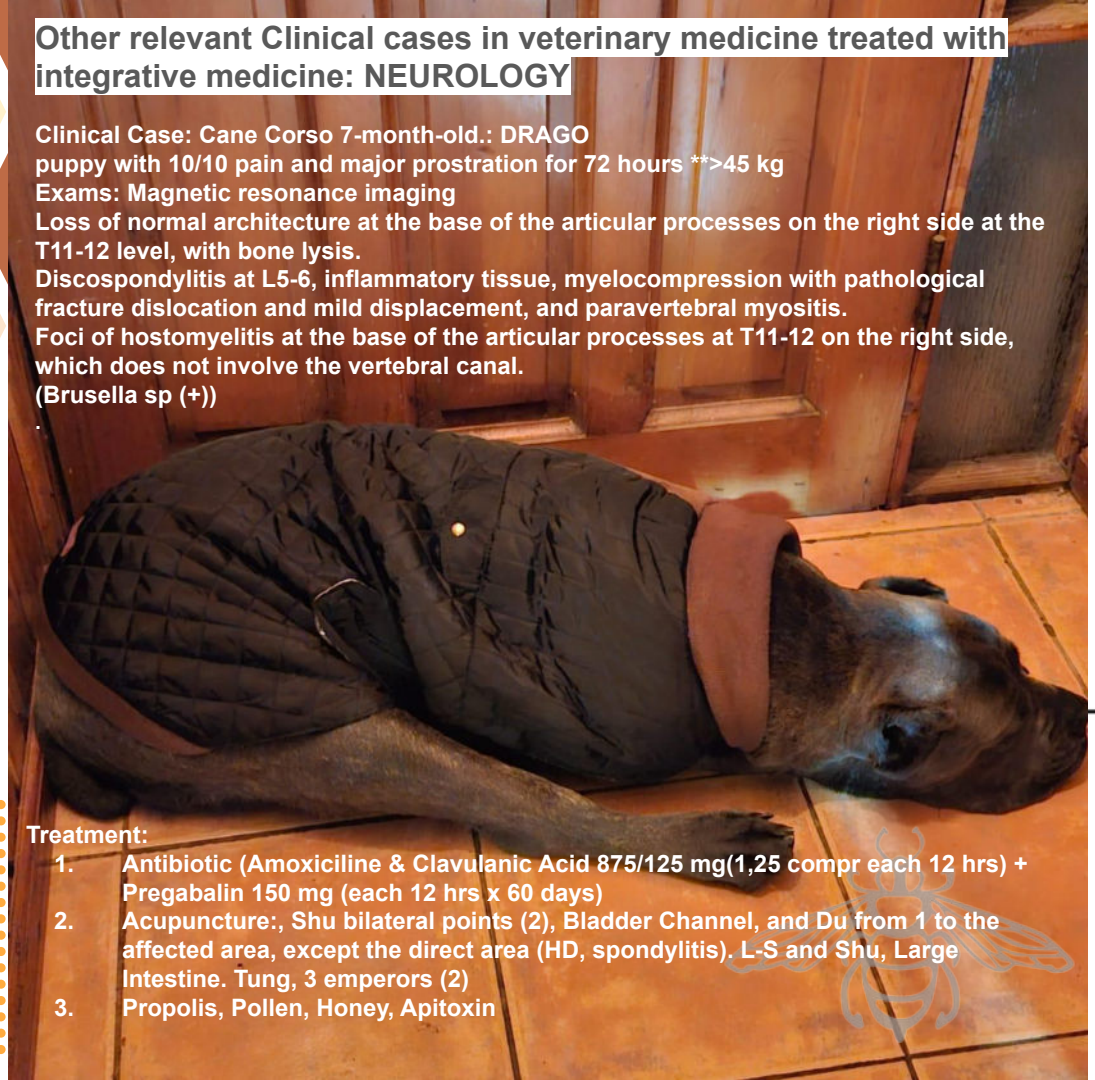

Treatment:

1. **Antibiotic (Amoxiciline & Clavulanic Acid 875/125 mg(1,25 compr each 12 hrs) + Pregabalin 150 mg (each 12 hrs x 60 days)**
2. **Acupuncture:, Shu bilateral points (2), Bladder Channel, and Du from 1 to the affected area, except the direct area (HD, spondylitis). L-S and Shu, Large Intestine. Tung, 3 emperors (2)**
3. **Propolis, Pollen, Honey, Apitoxin**

CENTRO IMAGENVET

INFORME RESONANCIA MAGNÉTICA

Paciente	Drago	**Edad**	7 meses
Especie	Canina	**Sexo**	Macho
Raza	Cane Corso	**Fecha**	02-05-2025
Propietario	Gema Guenchur		
Médico Solicitante Dr.(a)	Sofia Drücker		
Motivo de examen	Paraparesia y dolor toracolumbar, crónico		

ESTUDIO:

Resonancia Magnética de columna Lumbar.
Estudio realizado con cortes de 3.0 - 3.5 mm de espesor.
Plano sagital, dorsal y transversal
Secuencias T1 (pre y postcontraste), T2, STIR, 3DHyce, Myelocontrast, 3DSST1 (pre y postcontraste).
Medio de contraste: gadolinio.

DESCRIPCIÓN:

Columna vertebral:
- Pérdida de la arquitectura normal del espacio intervertberal T5-T6, con aumento de señal desestructurado en secuencia T2, STIR y postcontraste. Acortamiento de los cuerpos vertébrale T5 y T6, en su eje sagital, asociado a espondilolistesis. Presencia de tejido heterogéneo, isointenso en secuencia T1, levemente hiperintenso en secuencia T2 y STIR, con realce de señal postcontraste, sobre el espacio intervertebral. Esto último sumado a la espondilolistesis, generan estenosis del canal vertebral y leve mielocompresión, que s acompaña de exclusión de las líneas aracnoideas.
- Aumento de señal en secuencia T2 y STIR de los músculos epiaxiales e hipoaxiales a nivel de T5-T6.
- Pérdida de la arquitectura normal en la base de los procesos articulares del lado derecho, a nivel de T11-T12, con lisis ósea, que se aprecia hiperintenso en secuencia T2, STIR y T1 postcontraste.

El resto de los discos intervertebrales, muestran una señal conservada en secuencia T2 y STIR. Parénquima medular, sin modificación de señal en secuencia T2 y STIR.

ImagenVet – Servicio de Imagenología Veterinaria Móvil Concepción – contacto: imagenvet.contacto@gmail.com

IMPRESIÓN:

Discoespondilitis L5-L6, que se asocia a acortamiento de los cuerpos vertebrales, espondilolistesis, que en conjunto a presencia de tejido inflamatorio, se genera leve mielocompresión. Hallazgos que sugieren luxofractura patológica L5-L6, con leve desplazamiento. Mositis paravertebral a este nivel. Foco de osteomielitis en la base de los procesos articulares T11-T12 del lado derecho, que no compromete el canal vertebral.

Atentamente,

Dr. Javier Green
Médico Veterinario
SEDIVET














tesa


BUSTER



Cindy: female canine / French Bulldog
3 years.
Basis pathology: Intracranial tumor





The patient lost eyelid mobility and developed dry eye due to loss of ocular lubrication.





Acupuncture Shu Points Kidney - San Jiao, Stomach, Spleen, Liver.
Deep + Dr Tung Technique:Superior Dao Ma Jiao / stimulates soft and hard structures of the Anterior / Superior Jiao.
Corneal ulcer secondary to Absence of left eye blinking.





Endovenous Honey Therapy Manages to clean the internal bed, increase vital energy, nourish Qi; and act as a preparation for **Invasive therapy and carrier of high-quality injectable Apitoxin with direct antitumoral effect.**




Before Apitherapy & TCM


After Apitherapy & TCM

NEUROLOGY SNC: EPILEPSY

Morgan: 2-year-old Dalmatian dog; Epilepsy as a sequel to canine distemper.

Treatment: Acupuncture/TCM + Apitherapy:
Oral apitherapy; microdose injectable apitoxin post-allergy test (-) and intravenous honey in the second stage

The patient does not focus his gaze and has seizures daily.









The patient focuses his gaze and seizures decrease and finaly haven´t



Basic analysis of clinical cases in veterinary medicine treated with integrative medicine * Apitherapy by specialty:

Speciality	Number of cases	% of total	Type A	Type B	Type C
Dermatology	347	22%	68%	25%	7%
Neurology Spine HD	181	11%	78%	13%	9%
Reproductive Septic / OVH Castration Surgery	162	10%	69%	23%	8%
Intoxication / Hepatitis	153	10%	65%	24%	12%
Trauma, Polytrauma	113	7%	62%	19%	19%
Tumors, Cancer	94	6%	44%	19%	37%
Joint Pathology, Osteoarthritis	91	6%	76%	21%	3%
Reproductive Fertility	72	5%	76%	7%	17%
CNS and Distemper Sequelae	67	4%	64%	21%	15%
Digestive Metabolic	52	3%	65%	31%	4%
Renal Metabolic	49	3%	61%	37%	2%
Immune / Autoimmune	40	3%	55%	23%	23%
Respiratory	33	2%	45%	27%	27%
Ophthalmology	31	2%	74%	26%	0%
Infectious Diseases - Sepsis	27	2%	44%	52%	4%
Malnutrition	25	2%	72%	28%	0%
Gastrointestinal	25	2%	12%	68%	20%
Spinal Trauma	23	1%	83%	0%	17%



Specialties with Apimimedicine	1585	86%
General Treatments Preventive Medicine	262	14%
Total	**1847**	**100%**

A	Excellent therapeutic effect; Reversal of the clinical picture for which he comes
B	Good therapeutic effect; overcomes the initial state for which the patient comes
C	Little or no improvement in the state of health for which the person comes / or dies

Class	Total	%	
Type A	1.042	66 %	
Type B	359	23 %	
Type C	184	12 %	
Subtotal	**1.585**	**100 %**	
General treatments	262		14%
Total	**1.847**		100%



Daily seizures; rotating movements, constant restlessness, head banging









Patricio, 14, Refractory Epilepsy





Honey detox massage , Acupuncture, Apipuncture in Osteoarthritis, C2-3 fractures and herniated discs in 73 years old man.

2 months of treatment: Focuses, stays still, looks for me when I arrive, and is more attentive













Other effective TCM techniques for humans that provide detox and change the body's internal tissue, generating synergy in integrative treatments: Acupuncture & Apipuncture, Bloodletting, Honey massage for Detox, general TCM; Tung and Dr. Wang's Channel Theory in TCM.







Sponsors:

- M. Verdugo
- Dr. J. Leal
- Dr. A. Wartloof
- Dr. P. Leyton
- La Ina

Api THANKS & we continue !!!

Dr. María Alejandra López Pazos

- Veterinary Physician *
- Diploma in Traditional Chinese Medicine and Apitherapy / People
- Member of the Apitherapy Scientific Committee - APIMONDIA (Apitherapy in Veterinary Medicine)
- Council Member Specialty Committee of Apitherapy / World Federation of Chinese Medicine Societies
- TERAPIS ® / www.terapis.cl / @centrovetera
- centrovetera@gmail.com